

BHS guidelines for the treatment of marginal zone lymphomas: 2018 update

D. Bron, MD, PhD^{1,2}, M. Maerevoet, MD^{1,2}, E. van den Neste, MD, PhD^{1,3}, V. Delrieu, MD^{1,4}, F. Offner, MD, PhD^{1,5}, W. Schroyens, MD, PhD^{1,6}, A. van Hoof, MD, PhD^{1,7}, G. Verhoef, MD, PhD^{1,8}, J.B. Giot, MD⁹, J.P. Loly, MD¹⁰, A. Janssens, MD, PhD^{1,2,8}, C. Bonnet, MD, PhD^{1,11}

SUMMARY

Marginal zone lymphomas (MZL) are a heterogeneous subtype of indolent B-non-Hodgkin lymphomas that includes distinct entities:

- *Extranodal mucosa-associated lymphoid tissue lymphoma* arises in a variety of tissue but primarily in the stomach. They are usually localised and often associated with chronic antigenic stimulation by microbial pathogens. Eradication of the pathogen is a major part of the first-line therapy. The prognosis is excellent in early stages. In advanced stages, observation, anti-CD20 antibodies and/or cytostatic drugs are therapeutical approaches.
- *Nodal MZL* is usually confined in lymph nodes, bone marrow and peripheral blood. The prognosis is somewhat worse in this entity. Current recommendations suggest that they should be managed as follicular lymphomas.
- *Splenic MZL* is a unique entity involving the spleen, bone marrow and blood. Hepatitis infection should be eradicated before considering treatment. These lymphomas have an indolent behaviour, and only symptomatic patients should be treated by splenectomy and/or anti-CD20 antibodies.
- Two novel entities are described, non-chronic lymphocytic leukaemia monoclonal B-cell lymphocytosis, probably closely related to splenic MZL lymphoma, and a less well-defined provisional entity involving primarily the spleen called splenic B-cell lymphoma/leukaemia, unclassifiable, including splenic diffuse red pulp lymphoma and hairy-cell leukaemia variant.

This review will discuss separately the diagnosis, work-up and treatment of extranodal mucosa-associated lymphoid tissue lymphoma, nodal MZL and splenic MZL. These guidelines include the recently published ESMO consensus conference on malignant lymphoma.¹⁻³

(BELG J HEMATOL 2019;10(4):153-64)

INTRODUCTION & GENERAL CONSIDERATIONS

Marginal zone lymphoma (MZL) is a heterogeneous indolent B-non-Hodgkin lymphoma (NHL) and represents 11% of NHL (Figure 1). The incidence of MZL increases in older patients, MZL represents 26% of NHL 80+ years old patients.⁴ MZL currently includes distinct diseases, all arising from post-germinal centre marginal zone B cells and sharing a similar immunophenotype (CD20+, CD19+, CD22+, CD27+,

FMC7+, CD5-, CD10-, K or λ+) but displaying differences in terms of clinical presentation, molecular findings, treatment and prognosis.⁴

1. Extra nodal mucosa associated Lymphoid Tissue lymphoma (MALT)
2. Nodal marginal zone lymphoma (NMZL)
3. Splenic marginal zone lymphoma (SMZL)
4. Splenic- B-cell lymphoma/leukemia, unclassifiable

¹Department of Hematology, ²Institut Jules Bordet (ULB), Brussels, ³Cliniques Universitaires St Luc, Brussels, ⁴Hôpital de Jolimont, Haine St Paul, ⁵Universitair Ziekenhuis, Ghent, ⁶Universitair Ziekenhuis, Antwerp, ⁷AZ St Jan, Bruges, ⁸Gasthuisberg, Leuven, ⁹Department of Infectiology, Centre Hospitalier Universitaire, Liège, ¹⁰Department of Gastro-Enterology, Centre Hospitalier Universitaire, Liège, ¹¹Centre Hospitalier Universitaire, Liège, Belgium.

Please send all correspondence to: D. Bron, MD, PhD, Institut Jules Bordet, 1 Rue Héger Bordet, 1000 Bruxelles, tel: 32 25413232, email: dbron@ulb.ac.be.

Conflict of interest: The authors have nothing to disclose and indicate no potential conflict of interest.

Keywords: marginal zone lymphomas, MZL.

(SLLU), including splenic diffuse red pulp lymphoma (SDRLP) and hairy-cell leukemia variant (HCL-v)

5. Non CLL Monoclonal B Lymphocytosis (non CLL-MBL)

INCIDENCE

Mucosa-associated lymphoid tissue (MALT) lymphomas account for approximately 7.5%, nodal MZL (NMZL) for less than 2% and splenic MZL (SMZL) for less than 1% of B-cell lymphomas. This disease is often asymptomatic and does not always lead to general symptoms.

DIAGNOSIS

Diagnosis is based on histological, immunophenotypic, cytogenetic and molecular analyses of involved organs.

STAGING AND RISK ASSESSMENT (TABLE 1)

The assessment includes past history and clinical examination. A complete blood count with differentiation and lymphocyte immunophenotyping, biology with lactate dehydrogenase (LDH), β 2-microglobulin, electrophoresis of proteins and viral serologies (Hepatitis C/B virus [HCV/HBV], HIV) must be performed and, if clinically relevant, bacterial serology (*Borrelia*, *Helicobacter Pylori* (HP), *Chlamydia Psittaci*, *Campylobacter Jejuni*) and autoimmune antibodies. Bone marrow biopsy with immunophenotype is indicated for clinical stage I or II or pancytopenia (molecular and cytogenetic analyses are optional). A chest and abdominal CT scan or an MRI evaluate nodal or organ involvement.

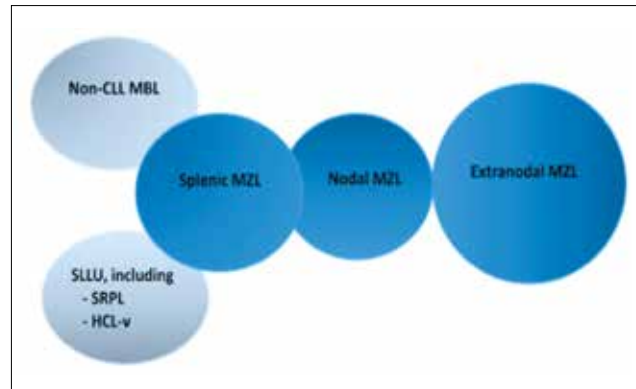


FIGURE 1. Non-Hodgkin lymphoma.

Hematology 2017:371-378 (Courtesy of C. Thieblemont).

MZL: marginal zone lymphomas, non-CLL MBL: non-chronic lymphocytic leukaemia monoclonal B-cell lymphocytosis, SLLU: splenic- B-cell lymphoma/leukaemia, unclassifiable, SRPL: splenic diffuse red pulp lymphoma, HCL-v: hairy-cell leukaemia variant.

Local evaluation by MRI is needed, especially for ocular site. Colonoscopy is mandatory in case of localised gastric lymphoma because multi-site lesions are observed in 50% of MALT lymphomas. In case of localised gastric lymphoma, an echo-endoscopy must be performed to define the loco-regional involvement of gastric lymphoma.

18 FDG PET/CT is not recommended for initial staging yet because the uptake can be low. However, it is currently

TABLE 1. Staging and risk assessment.

Lab tests: Complete blood cell count with differential and immunophenotype, biology with lactate dehydrogenase, β 2-microglobulin, electrophoresis of proteins, viral serology (HCV, HBV, HIV).

If clinically relevant: bacterial serology (*Borrelia*, *Helicobacter Pylori*, *Chlamydia Psittaci*, *campylobacter Jejuni*) and autoimmune antibodies.

Bone marrow biopsy with immunophenotype for clinical stage I or II or pancytopenia. Molecular and cytogenetic analyses are optional.

Lymph node biopsy with immunophenotype. Molecular and cytogenetic are optional.

Biopsy of any abnormal-appearing site.

Chest and abdominal CT scanner or MRI.

Local evaluation by MRI (especially for ocular site).

Gastro-colonoscopy in case of gastrointestinal involvement.

Echo-endoscopy in case of localised gastric lymphoma.

18 FDG PET/CT is not mandatory for initial staging yet (low uptake but can detect site).

TABLE 2. Differential diagnosis of B-lymphocytosis.

Cellular Marker	MALT lymphoma	FL	MCL	SLL/CLL	DLBCL
CD20	+	+	+	+	+
CD79a	+	+	+	+	+
BCL2	+/-	+	+	+	+/-
CD43	+/-	-	+	+	
CD5	-	-	+	+	
CD10	-	+	-	-	+/-
CD23	-	+/-	-	+/-	-
Cyclin D1	-	-	+	-	-
BCL6	-	+	-	-	+/-
Ig heavy chain	M>>A>G	G>M+D	M+D	M	Variable
CD21 and FDC meshwork	+	+	+/-	-	-

MALT: mucosa-associated lymphoid tissue, FL: follicular lymphoma, MCL: mantle-cell lymphoma, SLL: small lymphocytic lymphoma, CLL: chronic lymphocytic leukaemia, Ig: immunoglobulin, DLBCL: diffuse large B-cell lymphoma, CD: cluster of differentiation, FDC: Follicular dendritic cell.

performed at diagnosis to exclude sites of histological transformation.

A bone marrow biopsy is mandatory when there is peripheral monoclonal B-cell lymphocytosis (<5000/ microL) or cytopaenia. When a monoclonal B lymphocytosis is present in peripheral blood, other malignant hemopathies such as chronic lymphocytic leukaemia (CLL), hairy cell leukaemia (HCL), prolymphocytic leukaemia, follicular lymphoma and mantle cell lymphoma should be excluded by phenotypic (Table 2) and genetic analyses.

PROGNOSIS

Localised diseases can be cured after antibiotics administration, surgery or radiation therapy. Use of rituximab alone or in combination with chlorambucil (Chl), bendamustine, cyclophosphamide or cyclophosphamide + vincristine + prednisone (CVP) offers also an excellent prognosis for patients with disseminated diseases.

GASTRIC MZL (MALT TYPE)

MALT lymphomas represent 7-8% of all B-cell lymphoma (cfr World Health Organization [WHO] Book) and can arise at any extranodal site. However, at least 40% of them present

as a primary gastric lymphoma. Its development is usually associated with HP infection. **The prevalence of HP infection has decreased dramatically compared to the last couple of years, and as a result, the incidence of gastric MALT has decreased from 1.4 to 0.2/100,000 per year.**⁵ The median age is 60 years with a male predominance.⁶

The most common presenting symptoms of gastric MALT lymphoma are non-specific upper gastrointestinal (GI) complaints that often lead to an endoscopy usually revealing non-specific gastritis or peptic ulcer with unusual mass lesions. Diagnosis is based on the histopathologic evaluation of the gastric biopsies. If active HP infection is not demonstrated by histology (sensitivity >80%), it must be ruled out by a urea breath test and/or a stool antigen test. In addition to routine immunohistochemistry (CD20+, CD5-, CD10-), fluorescence *in situ* hybridisation analysis or polymerase chain reaction (PCR) may be useful for detection of t(11;18), identifying patients that are unlikely to respond to antibiotic therapy and with possible histological transformation. Other translocations like t(14;18), t(1;14) and t(3;14) are rarely observed.⁷

The initial staging procedures should include a gastroduodenal endoscopy with multiple biopsies taken from each

TABLE 3. NCCN Lugano staging system for Gastro-intestinal lymphomas.⁴²

Lugano staging system for Gastrointestinal lymphomas		Ann Arbor stage	TNM staging system adapted for gastric lymphoma	Tumor extension
Stage I _E	Confined to GI tract			
	I _{E1} = mucosa, submucosa	I _E	T1 N0 M0	Mucosa, submucosa
	I _{E2} = muscularis, propria, serosa	I _E	T2 N0 M0	Muscularis propria
		I _E	T3 N0 M0	Serosa
Stage II _E	Extending into abdomen			
	II _{E1} = local nodal involvement	II _E	T1-3 N1 M0	Perigastric lymph nodes
	II _{E2} = distant nodal involvement	II _E	T1-3 N2 M0	More distant regional lymph nodes
Stage II _E	Penetration of serosa to involve adjacent organs or tissues	II _E	T4 N0 M0	Invasion of adjacent structures
Stage III-IV	Disseminated extranodal involvement	III _E	T1-4 N3 M0	Lymph nodes on both sides of the diaphragm / distant metastases

region of the stomach and from any abnormal-appearing site. It is recommended to perform bacterial culture of the biopsy to choose the right antibiotics.

Endoscopic ultrasound is recommended to evaluate gastric wall infiltration and regional lymph nodes, also useful before irradiation. Colonoscopy is also recommended because multiple gastro-intestinal sites are detected in more than 50% of the gastric MALT lymphoma.⁸

This type of lymphoma has an unusual clinical course, the international prognostic index (IPI) is not correlated with overall survival (OS), and a specific staging system is now recommended by the National Cancer Comprehensive Network (NCCN) Lugano guidelines (Table 3).⁸

TREATMENT PLAN (TABLE 4-6, FIGURE 2)

Localized HP-positive gastric MALT lymphoma (stage IE-IIIE) often responds to eradication of HP infection with antibiotics + proton-pump inhibitor (PPI) as the sole initial treatment. Any of the highly effective anti-HP antibiotic regimens proposed can be used.

In case of unsuccessful HP eradication (breath test at 4-6 weeks after treatment, 1 week without PPI), a search for t(11;18) should be performed, because it is associated with a resistance to antibiotic eradication. A second-line therapy should be attempted with alternative triple- or quadruple-therapy regimens of PPI plus antibiotics. HP eradication can induce lymphoma regression and long-term clinical disease control

in 50-80% of patients. The length of time necessary to obtain a remission varies from 3 to 28 (median: 15.5) months. It is reasonable to wait at least twelve months before starting another treatment in patients who achieve a clinical and endoscopic remission together with eradication of HP but still with persistent (residual) lymphoma in the biopsy. Several studies of post-antibiotic molecular follow-up have shown the persistence of monoclonal B cells after histological regression of the lymphoma. In these cases, watchful waiting is recommended, while active anticancer treatment should be reserved for persistently symptomatic or progressive disease (level of evidence: III – recommendation A).⁹

Localised HP-negative gastric MALT lymphomas or patients who fail HP eradication therapy (stage IE-IIIE). There is no response to anti-HP antibiotic in HP-negative gastric MALT lymphoma. Gastric MALT lymphomas are usually localised, and excellent disease control using radiation therapy alone has been reported by several institutions supporting the use of modest-dose involved-field radiotherapy (24 Gy radiation to the stomach and perigastric nodes given in 12 fractions).¹⁰ Surgery has not been shown to achieve superior results in comparison with more conservative approaches in various trials (level of evidence: I – recommendation A).

Patients with systemic disease (stage III-IV). There is no clear evidence in the published literature to recommend any specific drug or regimen. These patients should be treated as advanced nodular MZL. There are no responses to anti-HP

TABLE 4. Treatment approach for pathogen-dependent marginal zone lymphoma.

GASTRIC MALT LYMPHOMA		
Helicobacter Pylori		
1 st line	2 nd line	3 rd line
1. PPI standard dose* /12h 2. Clarithromycin 500 mg/12h x 14d + amoxicillin 1 gr/12h x 14d + metronidazole 500 mg/12h x 14d Second choice: Quadritherapy**	Quadritherapy** Second Choice: 1. PPI standard dose* /12h 2. clarithromycin 500 mg/12h x 14d + Amoxicillin 1 gr/12h x 14d + metronidazole 500 mg/12h x 14d	Anti-biotherapy driven by sensitivity (biopsy for bacterial culture)
Borrelia Burgdorferi		
Doxycycline 100 mg/24h x 21d	Amoxicillin 1 g/12h x 21d	
Campilobacter Jejuni		
Clarithromycin 500 mg/12h x 7d	Azithromycin 500 mg/24h x 3d	Clindamycin 600 mg/8h x 7d
OCULAR MZL		
Chlamydia Psittaci		
Doxycycline 100 mg/24h x 21d		
SPLENIC MALT LYMPHOMA		
Hepatitis C Virus		
Treatment in collaboration with gastroenterologist No rituximab!		
<i>*standard dose= omeprazole 20 mg or esomeprazole 40 mg or lansoprazole 30 mg or pantoprazole 40 mg, **Quadritherapy= TRYPLERA® 3 gel/6h + omeprazole 20 mg/12h x 10 days, MALT: mucosa-associated lymphoid tissue, PPI: proton pump inhibitor, MZL: marginal zone lymphoma.</i>		

antibiotics in extra gastric MALT lymphoma in patients HP+. Lymphoma with diffuse large cell infiltration should be treated according to recommendations for diffuse large cell lymphomas.

RESPONSE EVALUATION AND FOLLOW-UP

Histological evaluation of repeated biopsies remains an essential follow-up procedure. Unfortunately, the interpretation of the lymphoid infiltrate in post-treatment gastric biopsies can be very difficult, and there are no uniform criteria for the definition of histological remission. A surveillance breath test or stool antigen test should be performed at least four weeks after the antibiotic treatment to document HP eradi-

cation (PPI must be stopped at least one week before HP testing). Then, a strict endoscopic follow-up is recommended, with multiple biopsies taken two to three months after treatment, and subsequently, at least twice a year for two years, to monitor histological regression of the lymphoma. Gastric MALT lymphomas have limited tendency to distant spreading and to histological transformation. Transient histological local relapses are possible but tend to be self-limiting especially in the absence of HP reinfection. In case of persistent but stable residual disease or histological relapse (without distant dissemination and/or gross endoscopic tumour), a watch-and-wait policy appears to be safe. Nevertheless, long-term careful endoscopic and systemic (blood counts and

TABLE 5. Approach for the treatment of pathogen-independent marginal zone lymphoma.^{12,28,30,32}

MALT LYMPHOMA
Localised Disease
<i>Surgery if not gastric</i>
<i>Local radiotherapy</i>
<i>Mono-agent therapy:</i>
First choice: R 375 mg/m ² /wk x 4
Second choice: Clb 6 mg/m ² /d, 5 d/mo x 6-12 mo
Alternative: Cyclophosphamide 100 mg/m ² /d x 6-12 mo
Disseminated disease
<i>Mono-agent therapy:</i>
See localised disease
<i>Poly-agent therapy:</i>
R-Clb x 6 months, RB every 4 weeks x 4**-6
NODAL MZL: treatment follicular lymphoma
Localised Disease
<i>Surgery</i>
<i>Local radiotherapy</i>
Disseminated disease
<i>Low tumour burden</i>
Watch and wait policy
<i>High tumour burden</i>
R-Clb x 6 months, BR 28 x 6, R-CVP21 x 8, R-CHOP21 x 6 + 2R
HEPATITIS C-negative SPLENIC MZL
<i>Asymptomatic patient</i>
Watch and wait policy
<i>Symptomatic patient</i>
Splenectomy, R 375 mg/m ² /week x 6 +/- maintenance 1/2 mo for two years, BR* every 4 weeks x 4**-6
<i>*if presence of adverse prognostic factors (high lactate dehydrogenase or B symptoms or presence of large cells (20-50%), **if complete response after three cycles.</i> <i>MALT: mucosa-associated lymphoid tissue, R: rituximab, Clb: chlorambucil, MZL: marginal zone lymphoma, BR: rituximab + bendamustine, R-CVP: cyclophosphamide + vincristine + prednisone, R-CHOP: rituximab + cyclophosphamide + doxorubicin + vincristine + prednisone.</i>

TABLE 6. Level of evidence (Infectious Diseases Society of American-United States Public Health Service Grading System).

Level of evidence	
I	Evidence from at least one large randomised controlled trial of good methodological quality (low potential for bias) or meta-analyses of well-conducted randomised trials without heterogeneity.
II	Small randomised trials or large randomised trials with a suspicion of bias (lower methodological quality) or meta-analyses of such trials or of trials demonstrated heterogeneity.
III	Prospective cohort studies.
IV	Retrospective cohort studies or case-control studies.
V	Studies without control group, case reports, experts opinions.
Grade for recommendation	
A	Strong evidence for efficacy with a substantial clinical benefit, strongly recommended.
B	Strong or moderate evidence for efficacy but with a limited clinical benefit, generally recommended.
C	Insufficient evidence for efficacy, or benefit does not outweigh the risk or the disadvantages (adverse events, costs, etc.), optional.
D	Moderate evidence against efficacy or for adverse outcome, generally not recommended.
E	Strong evidence against efficacy or for adverse outcome, never recommended.

minimal adequate radiological or ultrasound examinations) follow-up once per year is recommended for all patients. Indeed, patients with gastric MALT lymphoma have a six-fold higher risk than the general population of developing a gastric adenocarcinoma.

NON-GASTRIC MZL, MALT TYPE

MALT lymphomas arise in a number of epithelial tissues, including the stomach but also ocular annex (22%), lung (11%), salivary gland (3%), small bowel and colon (3%), thyroid (3%), parotid (3%) and skin (1%). Non-gastric extranodal MZL may also be associated with chronic immune stimulation by infectious agents (*Borrelia Burgdorferi*, *Chlamydia Psittaci*, *Campylobacter Jejuni*, hepatitis C) or autoimmune disorders.¹¹⁻¹³ The most common presenting symptoms of non-gastric MALT

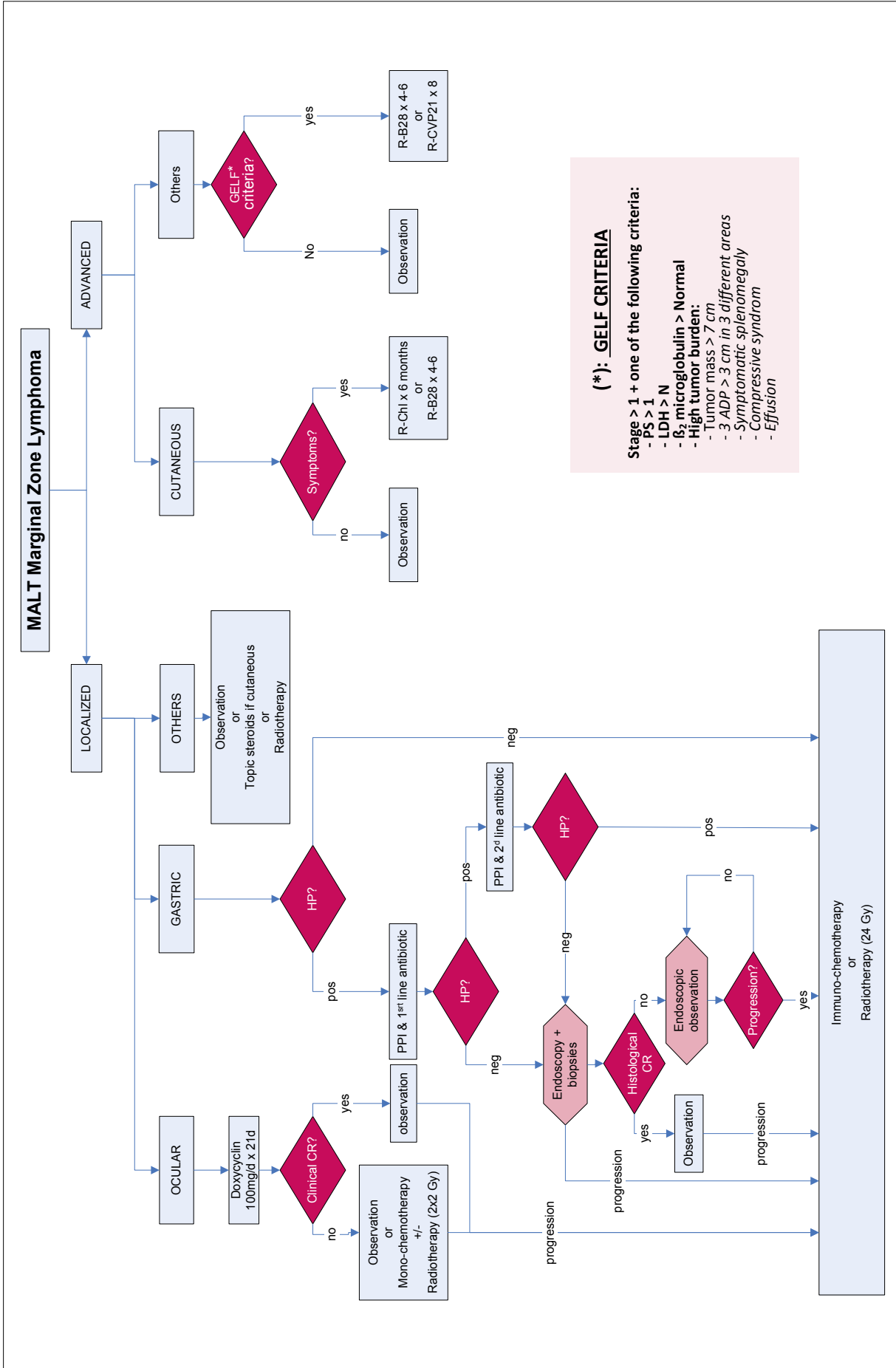


FIGURE 2. Treatment approach for mucosa-associated lymphoid tissue marginal zone lymphoma. MALT: mucosa-associated lymphoid tissue, GELF: Groupe d'Etude des Lymphomes Folliculaires, HP: *Helicobacter Pylori*, PPI: proton-pump inhibitor.

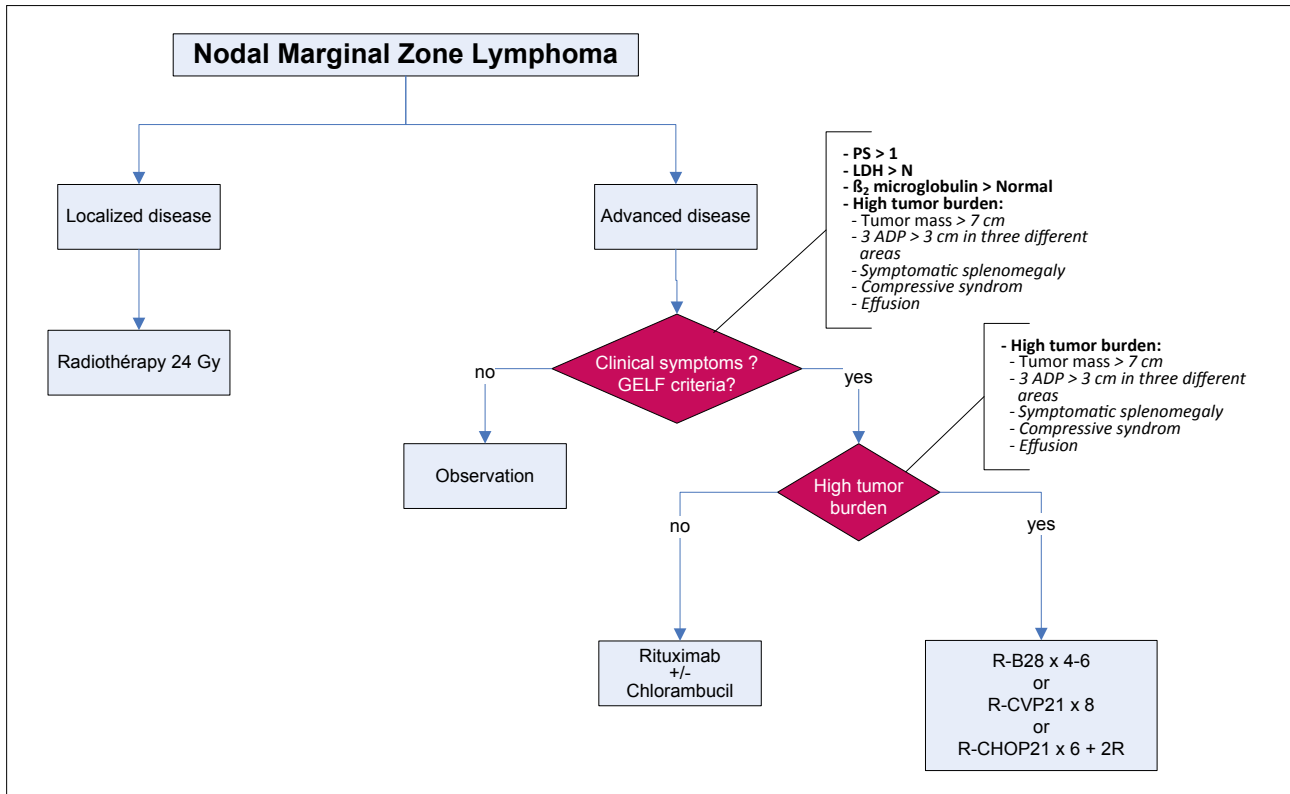


FIGURE 3. Treatment approach for nodal marginal zone lymphoma.

GELF: Groupe d'Etude des Lymphomes Folliculaires, LDH: lactate dehydrogenase, N: normal, R-CHOP: rituximab + cyclophosphamide + doxorubicin + vincristine + prednisone.

lymphoma are non-specific complaints. Median age at diagnosis is 60 years. Diagnosis is based on the histopathologic evaluation of the biopsies. *Campylobacter Jejuni* in the small intestine can be detected by PCR in the setting of immunoproliferative small intestinal disease. Viral and bacterial serologies are required to exclude active chronic stimulation (*Borrelia burgdorferi*, *Chlamydia*, *Campylobacter*). However, serologies are usually negative and molecular techniques should be performed to exclude these pathogens. The majority of patients present with localised stage I or II disease; 25% have bone marrow involvement; and 30% show a monoclonal immunoglobulin, more frequently IgG than IgM.

The initial staging procedures should include multiple biopsies taken from each abnormal-appearing site. The value of a PET scan is controversial and is useful mostly to detect sites of histological transformations.

TREATMENT PLAN (TABLE 5, FIGURE 2)

Limited stage extranodal MALT (stage I-II) includes those patients with involvement of a single extra-lymphatic site or a lymph node extending into a contiguous extra-lymphatic organ or tissue.

Surgery may be used as initial therapy for early stage MALT

in locations not amenable to radiation, although with the low doses of radiation required, nearly all sites can be treated. While surgery is not the initial treatment of choice for extranodal MALT, the pathologic diagnosis of MALT may become apparent only after a resection has taken place. If an extranodal MALT lymphoma is diagnosed with an excisional biopsy with negative margins, patients may be followed with close observation. However, if an initial surgical specimen demonstrates positive margins, adjuvant involved field radiotherapy (RT) should be administered to avoid local recurrence. *Loco-regional* RT with 24 to 30 Gy is the recommended treatment for most cases of limited stage extranodal MALT. This lymphoma is highly radiosensitive and doses should not exceed 30 Gy. With this approach, complete responses are seen in >90% of cases. Relapses are most commonly seen in the contralateral paired organ or in a distant site. Even for ocular MALT, radiation doses of 25 to 30 Gy are used with excellent outcome. In recurrent diseases or advanced diseases, lower dose of 4 Gy in two fractions may be effective for palliation.

Adjuvant-chemotherapy, applied after radiotherapy and/or surgery when lesions are not completely cleared or margins not negative.

Chlamydia Psittaci is detected (tumour tissue or conjunctival swab) in up to 89% of ocular adnexal lymphoma. Doxycycline at a dose of 100 mg for three weeks is reported for *Chlamydia Psittaci* eradication with 65% of lymphoma regression. This treatment is still under investigation but should be recommended because of its low toxicity.

In cutaneous MZL, there is no clear treatment recommendation due to the lack of prospective data. A localised nodule should be treated by RT (24-30 Gy). Radiation does not appear inferior to multi-agent chemotherapy among patients with multiple lesions that can be included in multiple radiation fields. Chemotherapy is required for extensive disease. An asymptomatic multifocal disease may be followed with close observation. In symptomatic disease, RT of the symptomatic sites can be useful.¹⁴

The MALT-IPI score including three risk factors (age >70 years, stage III-IV and elevated LDH) can discriminate patients with a very high risk to have a very short time of progression free survival (PFS) and OS after anti-CD20 antibodies and may be of help to select the patients that need more intensive treatment.²²

Extended extranodal MALT (stage III-IV) disease should be treated according to the International Extranodal Lymphoma Study Group (IELSG) trial recommendations: rituximab + Chl as updated in the Journal of Clinical Oncology.²⁴

RESPONSE EVALUATION AND FOLLOW-UP

Histological evaluation of repeated biopsies remains an essential follow-up procedure for intestinal lymphomas. In the case of persistent but stable residual disease or histological relapse (without distant dissemination and/or voluminous endoscopic tumour), a watch-and-wait policy appears to be safe. In all other cases, long-term careful examination of extranodal organs (MALT) and systemic (blood cells counts, adequate radiological or ultrasound examinations) follow-up once a year is recommended for at least five years.

NODAL MZL

NMZL represents 1% of all NHL and 10% of MZL. It presents primary nodal involvement in the absence of any extranodal site with the exception of bone marrow but produces in 30% of cases a monoclonal immunoglobulin (IgM>IgG). Median age at diagnosis is 50 years. The disease is often asymptomatic for many years, but in some patients, behaviour of the disease is more aggressive.^{2,15} In terms of molecular abnormalities, *NOTCH2* is mutated in 25% and *MYD88* in 10% of the patients.¹⁶ The immunoglobulin genes are clonally rearranged with a predominance of mutated *VH3* and *VH4* families. Mutations in the *JAK/STAT* pathway are described in 20%.¹⁷ A serum M-component is present in 10% of

patients.¹⁸ Hepatitis C virus and autoimmune diseases have also been reported in NMZL, including rheumatoid arthritis, vitiligo, systemic lupus erythematosus, autoimmune haemolytic anaemia, chronic thyroiditis and Sjögren's syndrome.¹⁵

TREATMENT PLAN (TABLE 5, FIGURE 3)

The general consensus regarding the treatment of NMZL is based on the approach of follicular lymphoma.¹⁹⁻²⁰ Criteria for treatment initiation are thus the Groupe d'Etude des Lymphomes Folliculaires (GELF) criteria (Stage II or more, LDH>normal limit, bulky mass, more than three lymph nodes above 3 cm, symptomatic splenomegaly, compressive mass).²¹ In asymptomatic cases, watchful waiting is recommended, while active anticancer treatment should be reserved for persistently symptomatic or progressive disease. Symptomatic patients should be treated with rituximab (either alone or in combination). Treatment with purine analogues might be associated with an increased risk of secondary myelodysplasia. Anthracycline-containing regimens are usually not necessary and should be reserved for the few patients with a high tumour burden or transformed histologies.²³ In cases of low tumour burden, a watchful waiting strategy should be recommended.²² In cases of symptomatic disease, Chl (6 mg/m²/d x 6-12 months) or cyclophosphamide (100 mg/day) can result in a high rate of disease control. Immunotherapy is considered an appropriate option. Rituximab (R) combined with Chl is now proven to be superior to Chl alone in PFS (58% at 5 years) but not in OS.²⁴ In case of high tumour burden, more intensive treatment as R-CVP or R-bendamustine (BR) should be considered. BR is effective for both extranodal MZL and NMZL with 98% CR and 93% PFS at 7 years. In a phase III trial comparing R-CHOP (cyclophosphamide + doxorubicin + vincristine + prednisone) to BR, after a follow-up of 45 months, the median PFS is longer in the BR arm (69.5 vs 31 months) and less frequently associated with serious side effects. In case the patient achieves a CR after three courses of BR, BR can be discontinued after four cycles.²⁵ Rituximab maintenance improved PFS in a recent phase II trial presented by Rummel (ASCO 2018) in NMZL and SMZL but without benefit in survival, and the results are not yet published. Rituximab combined with lenalidomide is a chemo-free effective treatment (90% overall response [OR] in first-line treatment and 70% CR).²⁶ PI3 kinase inhibitors (idelalisib and copanlisib) and mTor inhibitor everolimus are associated with \pm 50% OR but also with a high level of toxicity.²⁷⁻²⁸ Bruton's tyrosine kinase inhibitor ibrutinib shows an 50% OR (3% CR) with a PFS of 14 months. Ibrutinib is currently approved by the Food and Drug Administration (level of evidence: III – recommendation B).²⁹⁻³⁰

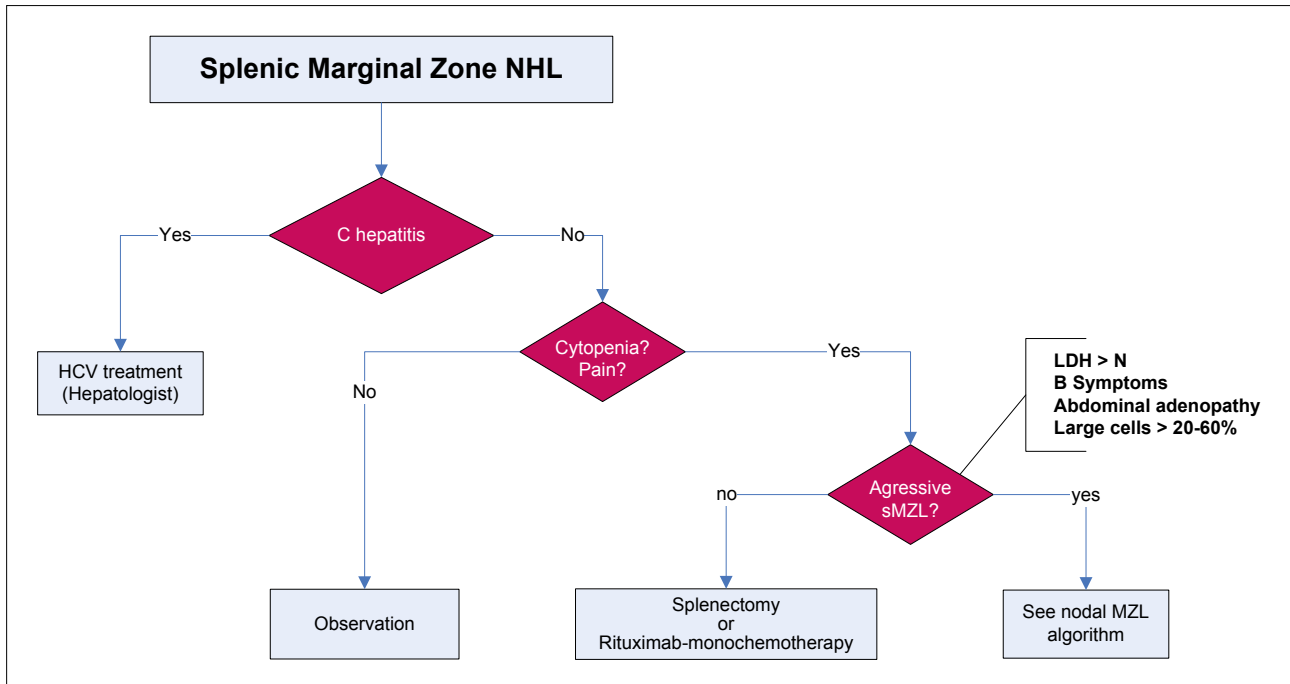


FIGURE 4. Treatment approach for splenic marginal zone lymphoma.

NHL: non-Hodgkin lymphoma, sMZL: splenic marginal zone lymphoma, HCV: hepatitis C virus, LDH: lactate dehydrogenase, N: normal.

The percentages of high-grade transformation (HGT) are 17.2% in NMZL versus 11.4% in SMZL and 6.4% in MALT ($p=0.05$). Patients presenting with HGT within 12 months from MZL diagnosis had a shorter OS compared to patients with late HGT (five-year OS rate 0.50 [95% CI 0.19-0.75] vs 0.75 [95% CI 0.49-0.89], $p=0.0192$). Lymphoma with diffuse large cell infiltration should be treated according to recommendations for diffuse large cell lymphomas.³¹

SPLENIC MZL

SMZL is a unique entity (<1% NHL, <10% of MZL) of low-grade lymphoma infiltrating spleen, hilar lymph nodes, bone marrow and peripheral blood. Peripheral lymph nodes are not typically involved. Median age is 70 years old with a female predominance.^{2,32} 10-40% of the patients has a serum monoclonal protein. The most common presenting symptoms of splenic MZL are non-specific abdominal complaints that often lead to an abdominal ultrasound or CT, usually revealing splenomegaly or a routine blood cell count revealing circulating monoclonal B lymphocytes in a healthy patient. This lymphoma has been reported in patients with HCV infection. Regression of the spleen was observed after eradication of the HCV. This represents a subset of SMZL associated with chronic hepatitis C and mixed cryoglobulinaemia. Many cases of SMZL are not hepatitis C driven. Approximately 40% of SMZL is associated with deletion of chromo-

some 7q32. Trisomy 3 is frequently associated with SMZL. Furthermore, 14q aberrations and TP53 deletions are also poor prognostic indicators. The majority of patients demonstrate an indolent course with a median OS exceeding 10 years. In 25-30% of patients, an aggressive behaviour is observed with a shorter survival. Factors associated with a shorter survival are elevated LDH, low haemoglobin level, older age and high IPI.

TREATMENT PLAN (TABLE 5, FIGURE 4)

Patients with HCV infection should be treated with modern antiviral therapy and not with rituximab.^{33,34} For all the other patients, treatment is indicated only in case of symptomatic disease (symptomatic splenomegaly, anaemia <10 gr/dL, thrombocytopenia <80000/microL, severe lymphocytosis, immune disorders [auto-immune haemolytic anaemia, immune thrombocytopenia], elevated LDH, B symptoms). Excellent disease control can be achieved by splenectomy or immunotherapy (rituximab). Splenectomy usually corrects pancytopenia and can lead to the reduction of circulating lymphocytes. Although it is a partial response, this situation can be maintained for a median of 10 years.³⁵ Treatment with single agent rituximab can result in a reduction of splenomegaly and normalisation of absolute lymphocyte counts in >90 % of patients.³⁶ Rituximab combined with bendamustine also produces durable responses (seven-year disease-

KEY MESSAGES FOR CLINICAL PRACTICE

- 1** Extranodal mucosa-associated lymphoid tissue (MALT) lymphoma arises in a variety of tissue but primarily in the stomach. They are usually localised and often associated with chronic antigenic stimulation by microbial pathogens. Eradication of the pathogen is part of the first-line therapy.
- 2** Prognosis of extranodal MALT is excellent and radiotherapy at a dose of 24-30 Gy is curative in early stages. In advanced stages, observation, anti-CD20 antibodies and/or cytostatic drugs (such as chlorambucil or bendamustine) are therapeutical approaches. The MALT-IPI score can discriminate patients with a very high risk to have a very short time of progression free survival and overall survival.
- 3** Nodal marginal zone lymphoma is usually confined in lymph nodes, bone marrow and peripheral blood. Because of the lack of randomised controlled trials in this population, there are no guidelines, and they should be managed as follicular lymphomas. Fludarabine regimen is too toxic and not recommended in first-line therapy.
- 4** Transformation in high grade lymphoma should be treated as general recommendation for diffuse large B-cell lymphoma based on anthracycline regimen (R-CHOP).
- 5** Splenic marginal zone lymphoma has an indolent behaviour. Patients with active hepatitis C benefit from antiviral therapy and do need immediate cytoreductive treatment. Only symptomatic patients should be treated by splenectomy and/or rituximab-based regimen.

free survival of 75%) with acceptable toxicity.²³ There have been a few series reporting improved symptoms after splenic irradiation or embolisation when the patient is not chemosensitive and not candidate for splenectomy.³⁷

SPLENIC RED PULP LYMPHOMA

Splenic red pulp lymphoma (SRPL) is a rare entity that has recently been included in the updated WHO classification.³⁸ It affects men (M/F ratio: 1:6) with a median age of 77 years and is characterised by a lymphocytosis with a heterogeneous phenotype very similar to HCL variant (v-HCL) with a weak CD25 and a strong CD11c expression. The karyotype frequently reveals a 7q deletion but *BRAF* mutations are absent. There is no clear therapeutic recommendation for these patients, and the clinical course can be indolent. Usually, SRPL patients do not receive systemic treatment, and they can be managed with splenectomy. In rare cases, cytotoxic chemotherapy with or without rituximab is used with variable results.³⁹

HAIRY CELL LEUKAEMIA VARIANT

v-HCL is a rare entity that represents 10% of all HCL cases. This disorder must be dissociated from the classical HCL especially because of its different molecular signature and the poor clinical outcome of patients with v-HCL. It mainly affects old men with a median age of 71 years. Leucocytosis

is generally high in more than 90% of cases. Monocytopenia is absent. The HCL score is low with strong expression of CD11c and CD103 but weak CD25. The *BRAF* mutation is also absent, while *TP53* mutations can frequently be detected. The *IGHV* is more frequently unmutated with the *IGHV4-34* rearrangement. In addition to this, there is a high prevalence of mitogen-activated protein kinase 1 (*MAP2K1*) mutations in this patient population. There is no consensus for the best therapeutical approach.⁴⁰⁻⁴¹

CONCLUSIONS

Marginal zone lymphomas are a heterogeneous group of indolent NHL. Extranodal MZL arises more frequently in the stomach where it is often associated with HP. NMZL behaves as follicular NHL and should be managed with similar approaches. SMZL usually presents with peripheral blood and bone marrow involvement. HCV virus can be associated with SMZL.

REFERENCES

1. Thieblemont C. Improved biological insight and influence on management in indolent lymphoma. Update on nodal and splenic marginal zone lymphoma. *Hematology Am Soc Hematol Educ Program*. 2017;2017(1):371-8.
2. Dreyling M, et al. ESMO Consensus conferences: guidelines on malignant lymphoma. Part 2: marginal zone lymphoma, mantle cell lymphoma, peripheral T-cell lymphoma. *Ann Oncol*. 2013;24(4):857-77.

3. Robak T, et al. Hairy cell leukemia: ESMO clinical practice guidelines. *Ann Oncol*. 2015;26(Suppl 5):100-7.
4. Thieblemont C, et al. Non-Hodgkin's lymphoma in very elderly patients over 80 years. A descriptive analysis of clinical presentation and outcome. *Ann Oncol* 2008;19(4):774-9.
5. Raderer M, et al. Antibiotic treatment as sole management of *Helicobacter pylori*-negative gastric MALT lymphoma: a single center experience with prolonged follow-up. *Ann Hematol*. 2015;94(6):969-73.
6. Ferreri AJ, et al. Primary gastric lymphoma pathogenesis and treatment: what has changed over the past 10 years? *Br J Hematol*. 2007;136(4):521-38.
7. Kwee I, et al. Genomic profiles of MALT lymphomas: variability across anatomical sites. *Haematologica*. 2011;96(7):1064-6.
8. Xu X, Wang Z, Yu Y, et al. Evaluation of the clinical characteristics and prognostic factors of gastrointestinal mucosa-associated lymphoid tissue (MALT) lymphoma. *J Gastroenterol Hepatol*. 2014;29(9):1678-84.
9. O'Connor A, Vaira D, Gisbert JP, et al. Treatment of *Helicobacter pylori* infection. *Helicobacter* 2014;19(suppl 1):38-45.
10. Lowry L, Smith P, Qian P, et al. Reduced dose radiotherapy for local control in Non-hodgkin lymphoma, A randomised phase III trial. *Radiother Oncol*. 2011;100(1):86-92.
11. Kiesenwetter B, et al. Antibiotic therapy in nongastrointestinal MALT lymphomas: A review of the literature. *Blood*. 2013;122(8):1350-57.
12. Kiesenwetter B, et al. AGMT Investigators. A phase 2 study of rituximab plus lenalidomide for mucosa-associated lymphoid tissue lymphoma. *Blood*. 2017;129(3):383.
13. Ferreri AJ, et al. *Chlamydomyxa Psittaci* eradication with doxycycline as first-line targeted therapy for ocular adnexae lymphoma: Final results of an international phase II trial. *J Clin Oncol* 2012;30(24):2988-94.
14. Wilcox RA. Cutaneous B-cell lymphomas: 2013 update on diagnosis, risk stratifications and management. *Am J Hematol*. 2013;88(1):74-6.
15. Van den Brand M, et al. Recognizing nodal marginal zone lymphoma: Recent advances and pitfalls. A systematic review. *Haematologica*. 2013;98(7):1003-13.
16. Rossi D, et al. The coding genome of splenic marginal zone lymphoma: activation of NOTCH2 and other pathways regulating marginal zone development. *J Exp Med*. 2012;209(9):1537-51.
17. Spina V, et al. The genetics of nodal marginal zone lymphoma. *Blood*. 2016;128(10):1362-73.
18. Pileri S, et al. Pathology of nodal marginal zone lymphomas. *Best Pract Res Clin Haematol*. 2017;30(1-2):50-5.
19. Federico M, et al. R-CVP versus R-CHOP versus R-FM for the initial treatment of patients with advanced-stage follicular lymphoma: Results of the FOLL05 trial conducted by the Fondazione Italiana Linfomi. *J Clin Oncol*. 2013; 31(12):1506-13.
20. Debussche S, et al. Guidelines of the Belgian Hematological Society for newly diagnosed and relapsed follicular lymphoma 2012. *Belg J Hematol*. 2012;3:41-50.
21. Solal-Céligny P, et al. Follicular lymphoma international prognostic index. *Blood*. 2004;104(5):1258-65.
22. Thieblemont C, et al. A MALT lymphoma-specific prognostic index. *Blood*. 2017;130(12):1409-17.
23. Rummel MJ, et al. Bendamustine plus Rituximab vs CHOP plus rituximab for patients with indolent and mantle cell lymphomas: an open label, multicenter, randomised, phase 3 non-inferiority trial. *Lancet*. 2013;381(9873):1203-10.
24. Zucca E, et al. Final results of the IELSG-19 randomized trial of Mucosa-associated lymphoid tissue lymphoma: improved event-free and progression-free survival with Rituximab plus chlorambucil versus either chlorambucil or rituximab monotherapy. *J Clin Oncol*. 2017;35(17):1905-12.
25. Laribi K, et al. The bendamustine plus rituximab regimen is active against primary nodal marginal zone B-cell lymphoma. *Hematol Oncol*. 2017;35(4):536-41.
26. Rummel J, et al. Two years Rituximab maintenance vs observation after first line treatment with bendamustine plus rituximab (B-R) in patients with marginal zone lymphoma (MZL): results of a prospective, randomized, multicentre phase II study (the StIL NHL7-2008 MAINTAIN trial). *J Clin Oncol*. 2018;36(15):7515.
27. Gopal AK, et al. PI3 α inhibition by idelalisib in patients with relapsed indolent lymphoma. *N Engl J Med*. 2014;370(11):1008-18.
28. Dreyling M, et al. European Mantle cell lymphoma network. The role of targeted treatment in mantle cell lymphoma: is transplant dead or alive? *Haematologica*. 2016;101(2):104-14.
29. Denlinger N, et al. Management of relapsed/refractory marginal zone lymphoma: focus on ibrutinib. *Cancer Manag Res*. 2018;10:615-24.
30. Noy A, et al. Targeting Bruton tyrosine kinase with ibrutinib in relapsed/refractory marginal zone lymphoma. *Blood* 2017;129(16):2224-32.
31. Alderuccio JA, et al. Outcomes in patients with marginal zone lymphomas undergoing transformation to high-grade lymphomas. *J Clin Oncol*. 2018; 36(15_suppl):7559.
32. Thieblemont C, et al. Splenic marginal zone lymphoma: current knowledge and future directions. *Oncology (Williston Park)*. 2012;26(2):194-202.
33. Hermine O, et al. Regression of splenic lymphoma with villous lymphocytes after treatment of hepatitis C virus infection. *N Engl J Med*. 2002;347(2):89-94.
34. Arcaini L, et al. Antiviral treatment in patients with indolent B-cell lymphomas associated with HCV infection: a study of the Fondazione Italiana Linfomi. *Ann Oncol*. 2014;25(7):1404-10.
35. Bennett M, et al. Treatment of splenic marginal zone lymphoma: Splenectomy versus rituximab. *Semin Hematol*. 2010;47(2):143.
36. Kalpadakis C, et al. Should rituximab replace splenectomy in the management of splenic marginal zone lymphoma? *Best Pract Res Clin Haematol*. 2018; 31(1):65-72.
37. Muylle K, et al. Radioembolization of the spleen: A revisited approach for the treatment of malignant lymphomatous splenomegaly. *Cardiovasc Intervent Radiol*. 2013;36(4):1155-60.
38. Swerdlow SH, et al. The 2016 revision of the World Health Organization classification of lymphoid neoplasms. *Blood*. 2016;127(20):2375-90.
39. Vig T, et al. A rare case of splenic diffuse red pulp small B-cell lymphoma (SDRPL): a review of the literature on primary splenic lymphoma with hairy cells. *Blood Res*. 2018;53(1):71-94.
40. Delrieu V, et al. BHS guidelines for the diagnosis and the treatment of hairy cell leukaemia. *Belg J Hematol*. 2017;8:222-8.
41. Letendre P, et al. Novel therapeutics in the treatment of hairy cell leukemia variant. *Leuk Res*. 2018;75:58-60.
42. Rohatiner A et al. *Ann Oncol*. 1994;5:397-400.